

Case Report

Title: "Management of Partially Impacted Mandibular Second Molars with an Australian Uprighting Spring."

Name:

1. Dr. JIGAR DOSHI BDS (MDS)

Post graduate student, Department of Orthodontics

Darshan Dental College and Hospital

drjigar009@yahoo.co.in

2. Dr. KALYANI TRIVEDI M.D.S

Professor & H.O.D, Department of Orthodontics

Darshan Dental College and Hospital

Drkalyani.trivedi@rediffmail. Com

3. Dr. TARULATHA S. M.D.S

Senior Lecturer, Department of Orthodontics

Darshan Dental College and Hospital

drdeepu20@yahoo.com

ADDRESS: Dr. Jigar Doshi

Department of Orthodontics and Dentofacial Orthopedics

Darshan Dental College and Hospital

Loyara, Udapiur

State: Rajasthan

Zip: 313001

INDIA

PHONE: +919928010230

Email: drjigar009@yahoo.co.in

Abstract:

Impaction of permanent teeth is a common clinical occurrence that may involve any tooth in the dental arch. The teeth most often impacted, in order of frequency, are the maxillary and mandibular third molars, the maxillary canines and the mandibular second molars. When found second molar impaction often presents a challenging problem to both the orthodontist and oral surgeon. A typical case of bilateral partially impacted mandibular molars is illustrated, with uprighting spring as a treatment option and different treatment modalities for impacted molars are discussed.

Keywords: Mandibular second molar impaction, Australian uprighting spring

INTRODUCTION:

Impaction of permanent teeth is a common clinical occurrence that may involve any tooth in the dental arch. The teeth most often impacted, in order of frequency, are the maxillary and mandibular third molars, maxillary canines and mandibular second molars.¹⁻⁴

Dachi and Howell¹ reported 16.7% of 3,874 routine full mouth radiographs showed impacted maxillary and mandibular third molars.

Mead² in his study found the incidence of impacted teeth in 1462 office cases, reported 89.2% third molar impactions and only 0.4% second molar impactions.

Other author like, **Karmer, Williams³** and **Aitasalo et.al.⁴** found most common impacted teeth are third molars and did not report any second molar impactions.

When found second molar impaction often presents a challenging problem to both the orthodontist and oral surgeon. Unilateral impaction of the mandibular second molar is more common than bilateral impaction and most frequently in mandible, found more often in males than females and frequently on the right side than left side. Impacted second molars are most commonly mesially inclined.⁵

Mandibular second molars erupt as a result of remodeling changes at the anterior border of the ramus after self-adjustments of their predetermined mesial axial inclinations. However, a lack of space in the arch due to inadequate mandibular growth, an undesirable axial inclination, or orthodontic treatment mechanics aimed at distalizing the first molars may prevent the natural self-correction of mesial inclination and result in impaction.

If the mesially impacted tooth is the third molar with first and second molars present, extraction may be the treatment of choice. If, however, one molar is missing, treatment of the impacted molar is mandatory to ensure a two-molar arch integrity for the patient.

Surgical repositioning of mesially impacted molars is a common procedure, but with the disadvantage of risking tooth vitality and/or root Ankylosis and resorption. Orthodontic eruptive guided mechanics is the treatment of choice. The procedure may become difficult if the tooth position is deep and horizontal, and other factors complicate the problem.

Purpose of this article to describe the use of the uprighting spring made up of 0.014 inch Australian Archwire to upright partially impacted mandibular second molar along with fixed orthodontic therapy.

Biomechanical Considerations:

The center of resistance of a molar without periodontal reduction is located in the bifurcation area. As the periodontal attachment is reduced, the CR moves apically. A force passing through the CR produces translation; (Fig 1). forces applied at crown level, as is usually the case in orthodontic treatment, will generate a moment, the magnitude of which equals the force times the perpendicular distance to CR. Uprighting depends on this moment to correct the inclination.

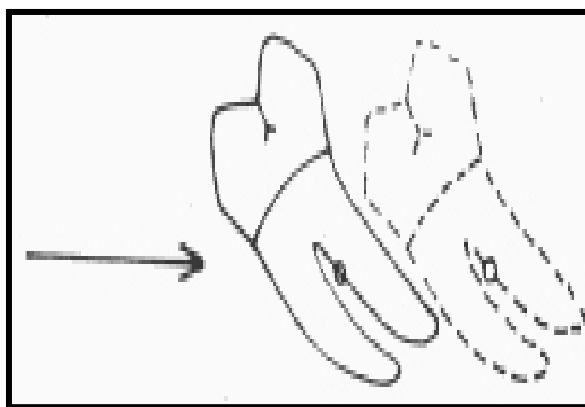


Fig 1: “Force application through the center of resistance through the center of a tooth produces translation.”

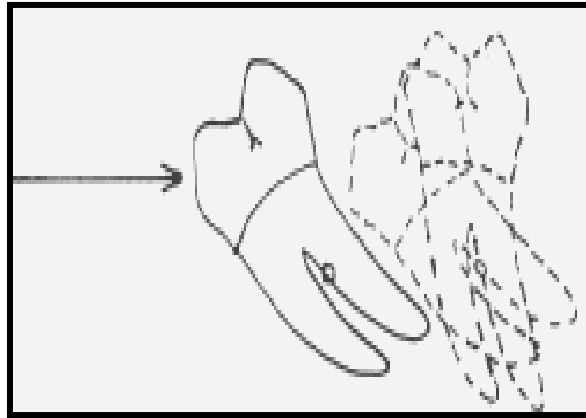


Fig 2: “Force application which pass above the center of resistance produces a combination of rotation and translation.

Spring produces effects on the tooth in three planes,

Mesiodistal direction result in distal crown tipping,

Vertical direction result in molar extrusion

Transverse plane result in buccal tipping of impacted molar and lingual tipping of supporting molar. (Fig 3)

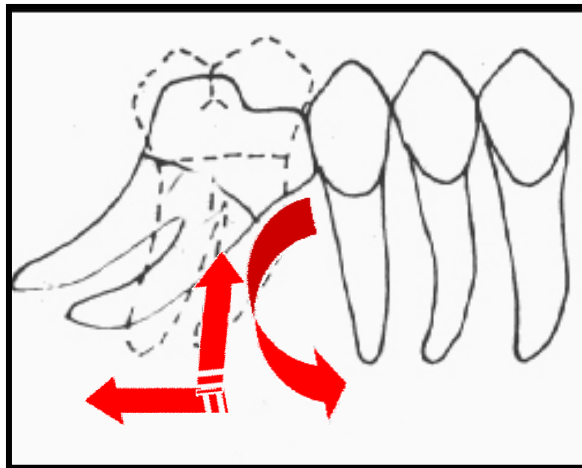


Fig 3: “effects of uprighting spring.”

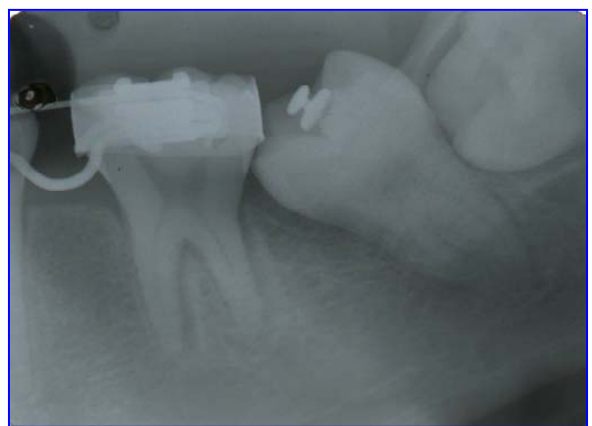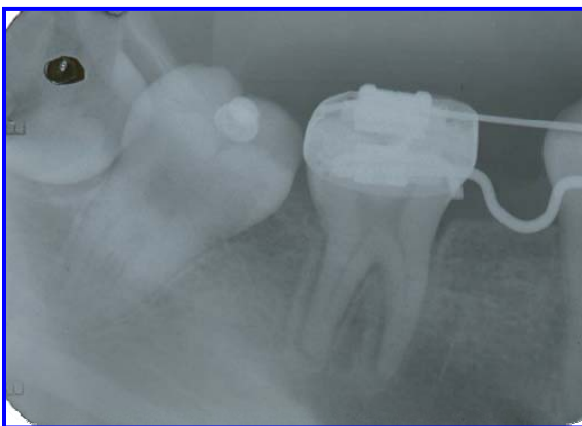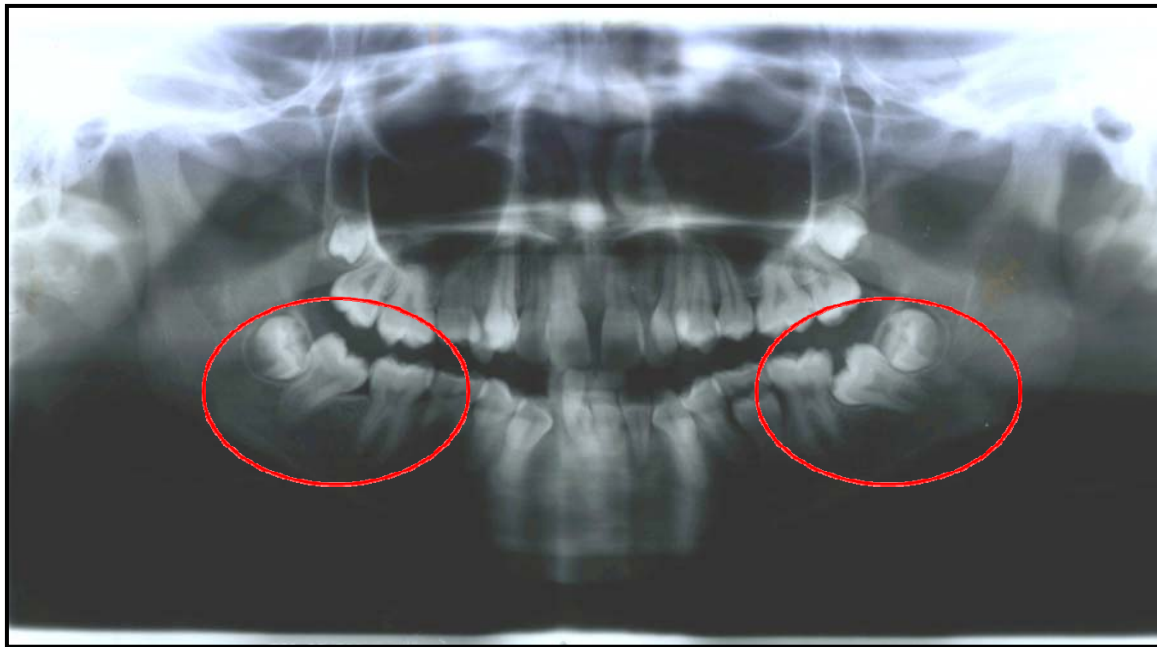
Undesirable forces acting on the anchorage molar are intrusive and lingual in nature, are resisted by a stiff archwire that dissipates it on the entire posterior segment of teeth. uprighting spring is made up of 0.014” australian premium plus SS wire. The forces generated are very light and relatively constant.

Case Report:

A **15 year old female** presented with bilateral partial impactions of the lower second molars. Patient was in mixed dentition stage with skeletal class III Jaw base relationship. She had bilaterally retained lower second deciduous molars with anterior crossbite and had severe crowding in the upper and lower arch with lingually displaced lower right lateral incisors.

Molar Uprighting

A panoramic radiograph, IOPA and lower occlusal view revealed the presence of all permanent teeth except right second premolar which was congenitally absent. Also, both lower second molars showed severe mesial inclination and were obliquely impacted under the distal bulge of the First molars. The apex of the impacted molar roots was completely formed. (Fig 4).



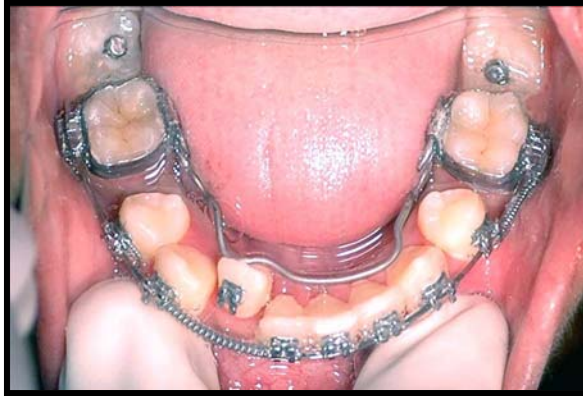


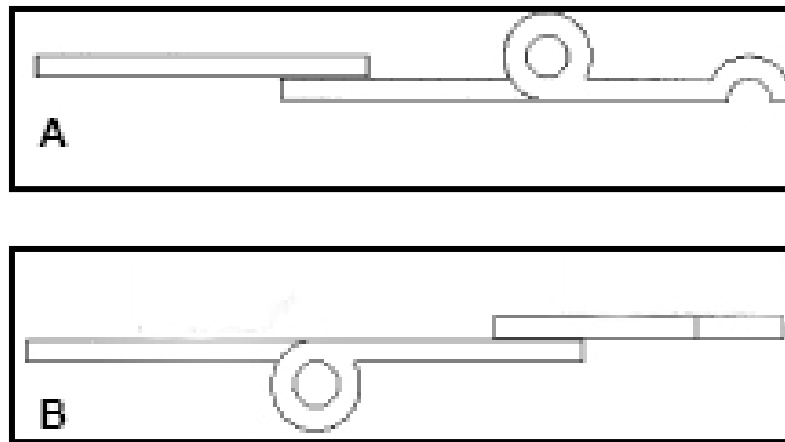
Fig 4: “Pre treatment Radiographs and lower Occlusal view.”

Treatment Procedure:

It was decided to extract upper first premolars, lower second deciduous molars and second premolar tooth bud. Treatment was started with fixed orthodontic therapy, using preadjusted Edgewise (MBT 022 slot”) appliance. After leveling and aligning of upper and lower arch, lower second molar uprighting was started with 019 x 025 SS as stabilizing archwire.

First step was to bond a lingual button to the exposed surface of the partially impacted second molar. Uprighting was done by using 014” australian SS wire.

A 40 mm long 0.014” australian SS wire was taken and molar stop was bent just distal to Auxillary tube of 1st molar. Distance from distal surface of auxillary tube to bonded button was measured and marked on a wire. (Fig 5)



Molar Uprighting

Fig 5: A) Occlusal view and B) buccal view of uprighting spring made up of 014” Aus. SS wire.

Coil of 3mm diameter was constructed with $2\frac{1}{2}$ circle to increase the length, flexibility and range of action of the wire. One more mark of same measurement was made on the wire distal to the coil. Now, hook was bent opposite to the direction of coil at the same distance. (Fig 5)

Insert a spring into the distal end of auxillary tube of molar until the molar stop contact the tube. Cinch the mesial end of the spring by bending down the wire on the mesial of the auxillary tube. It will prevent rolling effect and dislodgement of spring. Activation was done by engaging the hook to the bonded button on the impacted second molar.

At every 4 to 6 week, reactivation of the uprighting spring was done by disengaging and opening the coil and then re-engaging the hook. Progress should be seen rapidly after spring activation. (Fig 6,7,8)

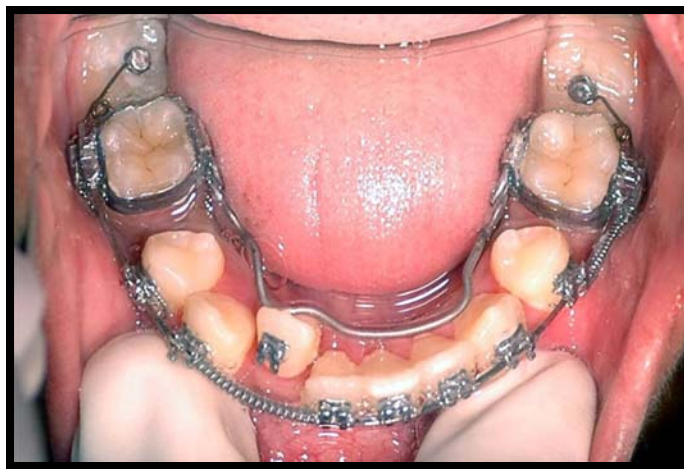
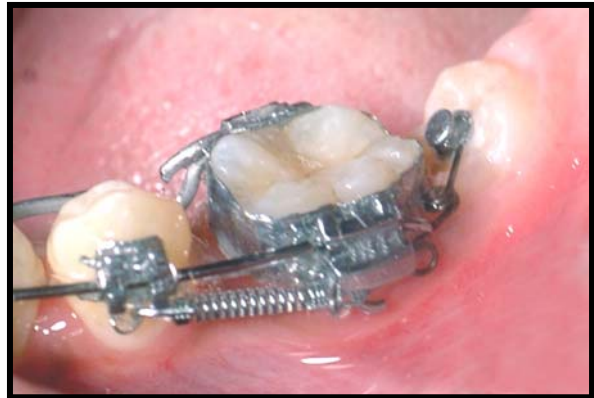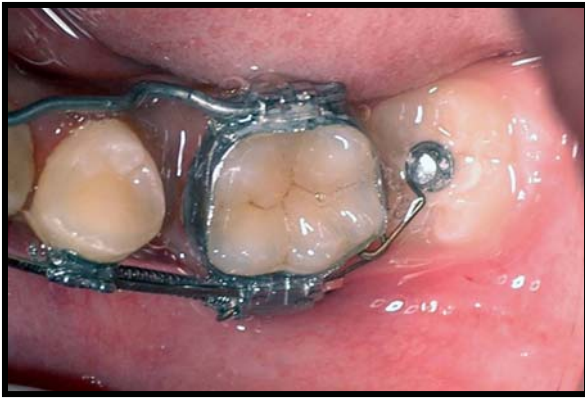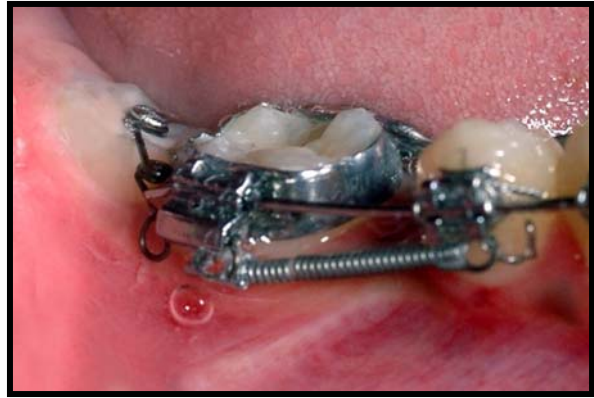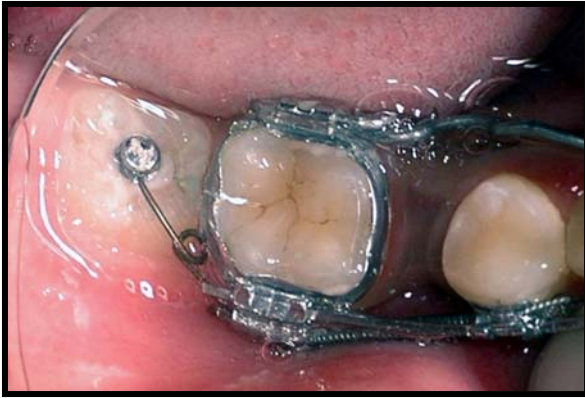


Fig 6: "spring activated by attaching hook to lingual button on impacted molars."

Molar Uprighting

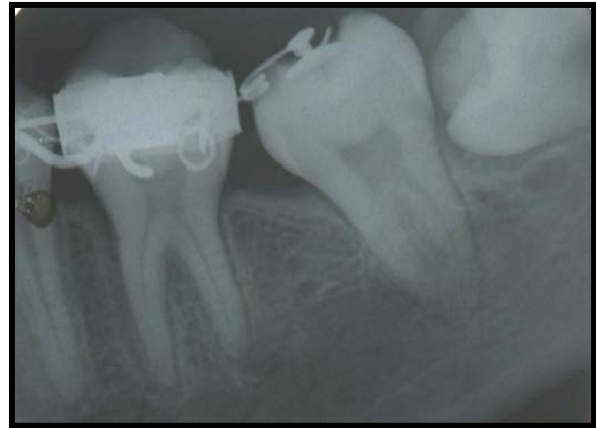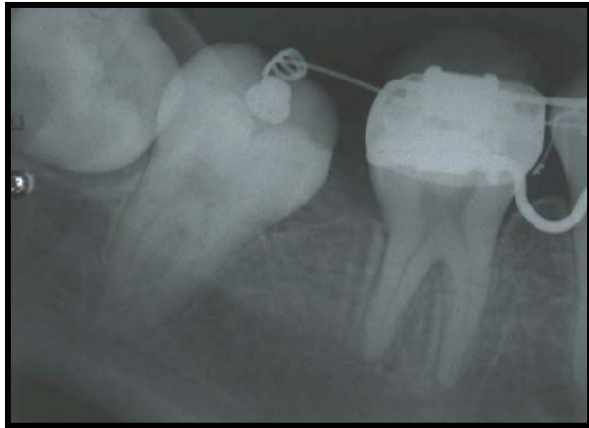
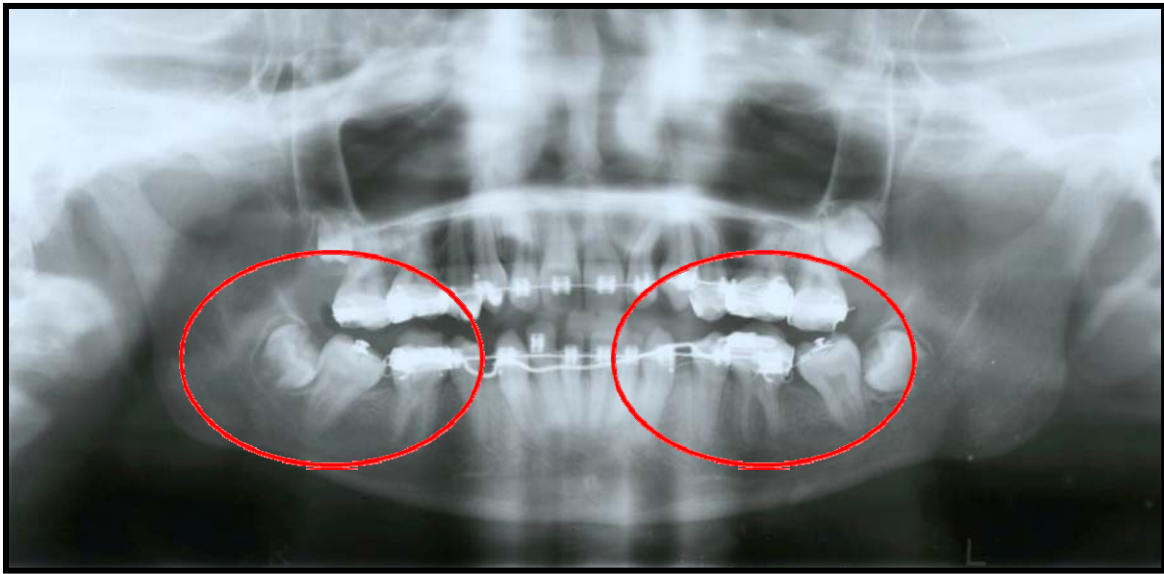

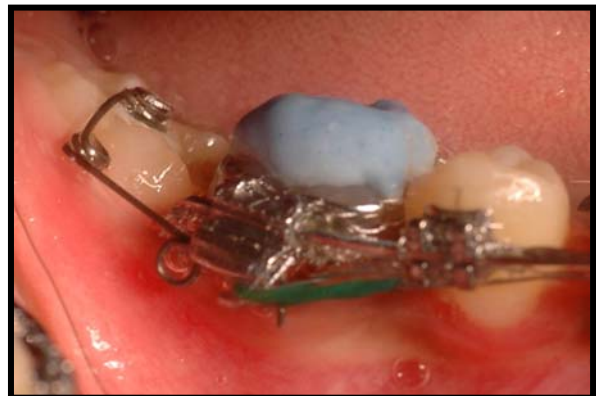
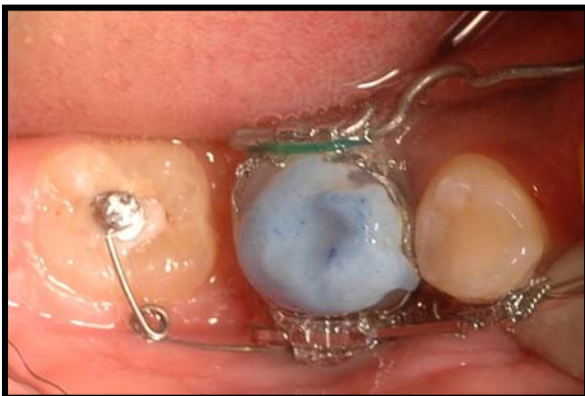Fig 7: "Post treatment OPG and IOPA."



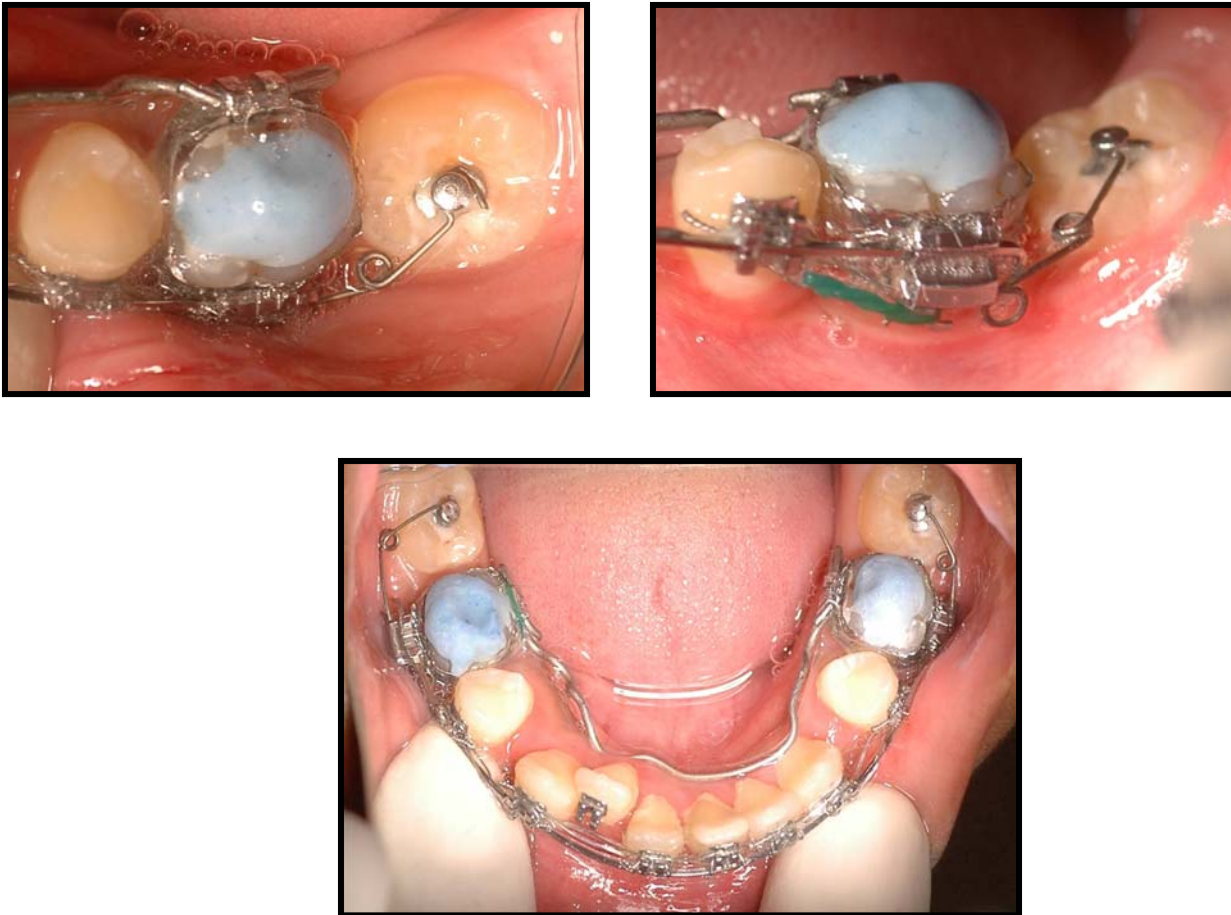


Fig 8: “Post treatment Photographs.”

Discussion:

Mesial inclination of the impacted mandibular second molar is much more common than distal inclination. Most of the cases reported in the literature show the unerupted mandibular second molar mesially inclined in an oblique or horizontal position, due to the initial mesial angulation of the developing tooth bud.⁶⁻⁸

Mandibular second molar impaction results from:

- Space gaining procedures in the mixed dentition.
- Arch length deficiency
- Extraction of adjacent first molar
- Premature mandibular third molar eruption
- Unusual angulation of the erupting second molar.

Proper time to treat these impactions is when the patient is 11 to 14 years old, during early adolescence when second molar root formation is still incomplete and before complete development of mandibular third molars.

Treatment modalities to correct the axial inclination of partially impacted permanent molars are,

- Orthodontic treatment modalities to upright and erupt the impacted second molar after exposure or without exposure.
- Surgical uprighting and repositioning of deep impacted second molar.⁸⁻¹⁶
- Extraction of second molar and allow eruption of third molar.⁸
- Extraction of Severely angulated and impacted second molar followed by immediate transplantation into the correct position or transplantation of third molar to the second molar socket.¹⁷⁻¹⁹

Various orthodontic treatment modalities to upright and erupt the impacted second molar after exposure or without exposure are,

1. Separating spring^{13,20}
2. De-impacting spring
3. Push-coil spring from first molar to second molar²¹
4. Push-coil spring with pins on the occlusal surface of the second molar²²
5. Boot-loop arch²³⁻²⁴
6. Mandibular full archwire with T loop²⁵
7. Lever arm from the second molar to the bicuspid^{8,26-28}
8. Bonded attachment to the second molar^{9,29-30}
9. Nickel titanium push coil from the bicuspid ("Distal Jet")³¹
10. Segmental Uprighting spring (Burstone)³²
11. Nickel titanium .016 x .022" wire inserted from the distal and anchored to the bicuspid region (MUST Appliance)³³
12. Nickel Titanium Uprighting Spring³⁴
13. Finger springs from a mandibular retainer³⁵
14. Use of Fixed "Eruption assisting" appliance³⁶

15. Using a soldered 0.036" lingual arch with occlusal rests on the bicuspids and an 0.036" distal extension ending in an eyelet.³⁷
16. Modified lingual arch and nickel titanium coil spring³⁸
17. Modified removable Transpalatal bar with E chain³⁹
18. Tip back Cantilever spring made up of 0.017 x 25 inch TMA wire.⁴⁰
19. Whip spring made up of 018 x 025 SS wire.³⁷
20. Crossed Tipback springs made up of 017 x 025 TMA wire.⁴¹
21. Piggyback buccal sectional archwire technique.⁴²
22. Improved pinning technique for elevating impacted teeth.⁴³
23. Use of titanium Microimplant as an anchorage at retromolar region.⁴⁴⁻⁴⁶
24. Surgical exposure followed by use of NiTi wire for uprighting.⁴⁷

The significant advantage of orthodontic uprighting technique is the distal tipping and uprighting of the impacted tooth without the necessity of surgical assistance, bone removal or splinting.

Method proposed here is a very simple and very efficient way to upright partially impacted second molars. By using this method, impacted molars will upright within 2-3 months.

Advantages:

- Simple to construct
- Requires no patient cooperation
- Activates easily.
- No laboratory work or impression are required
- Short treatment duration
- Because of the use of light and constant force will minimize the side effect on the anchor molars.
- No requirement of surgical exposure
- As the uprighting of the second molar achieved, rigid main archwire is replaced with the flexible arch wire including second molar to facilitate mesial root movement.
- Second molar never erupts above the occlusal plane

Conclusion:

Although surgical uprighting of impacted mandibular second molars appear to be a quick and easy procedure, orthodontic uprighting techniques are more advantageous and offer a better long term prognosis with no adverse pulpal or periodontal risk to the tooth or supporting structures. An adjunctive appliance design has been presented that proved to be effective, rapid acting, and simple. It can be used in conjunction with any

fixed appliance where auxiliary molar tubes are available. Nevertheless, every case may be different. It is important to recognize the components of the individual problems, the force system that is needed to achieve the specific goals, and finally the design of an appliance that will assure these objectives.

Bibliography :

1. Dachi SF, Howell FV: "A survey of 3,874 routine full mouth radiographs. A study of impacted teeth. Oral Surg Oral Med Oral Path 1961;14:1165-9
2. Mead S: "Incidence of impacted teeth." Int.J Orthod 1930;16:885-890
3. Karmer RM, Williams AC: "The Incidence of impacted teeth, Oral Surg. 1970;237-41.
4. Aitasalo K, Lehtinen R, Oksala E.: "An orthopantomographic study of prevalence of impacted teeth. Int.j oral Surg 1972;1:117-20.
5. Wellfelt B, Vaprio M.: "Disturbed eruption of the permanent lower second molar: treatment and results. J.Dent.Child 1988;55:183-9.
6. Friel S.: "Migration of teeth following extractions." Proc Roy Soc Med 1945;38:456.
7. Bjorling, Lundgren K.: "Migrating unerupted lower bicuspids." Odont Revy 1975;26:145-8.
8. Yehoshua Shapira, Geraid Borell, Oded Nahlieli et al.:"Uprighting mesially impacted mandibular permanent second molars, Angle Orthod. 1998;68(2):173-178.

9. Ferrazzini G.: "Uprighting of a deeply impacted mandibular second molar." Am.J.Orthod. 1989;96:168-171.
10. Porgel M.A: "Surgical uprighting of mandibular second molars." Am.J.Orthod. 1995;108:180-183.
11. Johnson E and Taylor R.C: "A surgical-orthodontic approach in uprighting impacted mandibular second molars, Am.J.Orthod 1972;61:508-514.
12. Nikos B. H, Anthimi T., Constantinos N: "Surgical correction of Mesially Impacted Mandibular Second Molars." J.Clin.Orthod 2003;37(4):209-212.
13. Albert H. Owen: "Early Surgical Management of Impacted Mandibular Second Molars. J.Clin.Orthod 1998;jul:446-450.
14. Laskin D.M and Peskin S.: "Surgical aids in orthodontics, Dent.clin.N.Am 1968:509-524.
15. Peskin S. and Graber T.M: "Surgical repositioning of teeth, J.Am.Dent.Assoc. 1970;80:1320-1326.
16. Davis, Patakas, Kaminishi et al.: "Surgically uprighting and grafting second molars." Am.J.Orthod. 1976:69:555-561.
17. Bishara, S.E and Burkey, P.S: "Second Molar extractions: A review, Am.J.Orthod 1986:89:415-424.
18. Liddle D.W: "Second molar extractions in orthodontic treatment. Am.J.Orthod 1977; 72:555-616.
19. Apfel H.: "Transplantation of the unerupted third molar tooth." J.Oral Surg. 1956;9:96.

20. Levitas T.C: "A simple technique for correcting an ectopically erupting first permanent molar, J.Dent.Child 1964;31:16-18,
21. Sinha P.K; Nanda R.S; Bazakidou, E: "Uprighting fully impacted second molars, J.Clin.Orthod. 1995; 29:316-318.
22. Howard J. Buchner: "Correction of Impacted Mandibular Second Molars." Angle Orthod. 1973;43(1):30-33.
23. Steven L. Cureton: "Second Molar Biomechanics." J.Clin.Orthod. 1995:Aug:500-508.
24. Smorntre Viteporne: "Stress distributions following Molar Uprighting." J.Lingual Orthod. 2002;2(1):13-21.
25. Tuncay OC, Biggerstaff RH, Cutcliffe JC: "Molar uprighting with T loop Springs." J.Amer.Dent.Assoc. 1980:100:863-6.
26. Melsen B., Fiorelli G, and Bergamini A: "Uprighting of lower molars." J.Clin.Orthod. 1996;30:640-645.
27. Rubin R.M: "Uprighting impacted molars." J.Clin.Orthod. 1977:11:44-46.
28. Orton H.S and Jones S.P: "Correction of mesially impacted lower second and third molars." J.Clin.Orthod 1987:21:176-181
29. Sufirstein G.R: "Unlocking impacted lower molars with direct bonding." J.Clin.Orthod. 1974; 8:205-212.
30. Rubenstein B.M: "Uprighting second molars with direct bonding." J.Clin.Orthod. 1975:9:377-378.
31. Carano A., Testa M. et al.: "The Distal Jet for uprighting lower molars, J.Clin.Orthod. 1996;30:707-710.

32. William Roberts, Frederic Chacker, Charles Burstone: "A segmental approach to mandibular molar uprighting." *Am.J.Orthod.* 1982;Mar:177-184.
33. Capelluto E., Lauweryns: "A simple method for molar uprighting." *J.Clin.Orthod.* 1997;31:119-125
34. Jon M.Kraut: "Nickel Titanium Uprighting Spring. *J.Clin.Orthod.* 1994:Jan:50-51.
35. Hanns, R.J:"Uprighting impacted mandibular second molars." *Angle Orthod.* 1975; 45:314-315.
36. David Resch: "Clinical Management of unilaterally impacted mandibular first and second molars." *J.clin.Orthod.* 2003;37(3):162-164.
37. David W. Warren: "Technique clinic correction of Impacted Mandibular second Molars. *J.clin.Orthod.* 1998;35(2):89-90.
38. Ata Umit Aksoy, Semure Aras: "Use of Nickel Titanium Coil Springs for Partially Impacted Second Molars." *J.clin.Orthod.* 1998;35(8):479-484.
39. Margherita S., Monica T., Nikos K.: "Modified Removable Transpalatal Bar for Rapid Uprighting of Impected Second Molars. *J.Clin.Orthod* 2002;Sept:496-499.
40. Monica Sawicka, Bonga Racka-P., Anna R.M: "Uprighting partially impacted permanent second molars." *Angle Orthod.* 2007; Vol 77(1):148-154.
41. Frank J.W, Hans-Peter B, Helmut Droschl: "Molar Uprighting with Crossed Tipback Springs." *J.Clin.Orthod.* 1992:Jan:1-7.
42. Melvin Kogod, Harold S.K: "Molar Uprighting with the Piggyback buccal sectional arch wire technique. *Am.J.Orthod.* 1991:Mar:276-280.
43. Marvin A. Prescott: "An Improved Pinning Technique for elevating impacted teeth. *J.Clin.Orthod.* 1968:Jan:24-27.

44. Aldo Giancotti, Fabiana Muzzi et. al.: "Miniscrew Treatment of Ectopic Mandibular Molars." *J.clin.Orthod.* 2003;july:380-383.
45. Hyo Sang Park, Hee-Moon Kung et. al.: "A Simple method of Molar Uprighting with Micro Implant Anchorage." *J.Clin.Orthod.* 2002;Oct:592-596
46. W.Craig Shellhart, Maged Moawad, Preston Lake: "Case report: Implants as anchorage for molar uprighting and intrusion." *Angle Orthod.* 1996; 3:169-172.
47. Going RE, Reyes Lois DB.: "Surgical exposure and bracketing technique for molar uprighting with the piggyback buccal sectional arch wire technique." *J. Oral Maxillofac. Surg.* 1999;57:209-212.